

## REVIEW ARTICLE

## CURRENT CONCEPTS

## ST-Segment Elevation in Conditions Other Than Acute Myocardial Infarction

Kyuhyun Wang, M.D., Richard W. Asinger, M.D., and Henry J.L. Marriott, M.D.

From the Hennepin County Medical Center, University of Minnesota, Minneapolis (K.W., R.W.A.); and the University of South Florida, Tampa (H.J.L.M.). Address reprint requests to Dr. Wang at the Hennepin County Medical Center, Cardiology Division, 701 Park Ave., MC 865A, Minneapolis, MN 55415.

N Engl J Med 2003;349:2128-35.  
Copyright © 2003 Massachusetts Medical Society.

**A**CUTE MYOCARDIAL INFARCTION RESULTING FROM AN OCCLUSIVE thrombus is recognized on an electrocardiogram by ST-segment elevation.<sup>1</sup> Early reperfusion therapy has proved beneficial in such infarctions.<sup>2-4</sup> The earlier the reperfusion, the greater the benefit, and the time to treatment is now considered to indicate the quality of care. These days, when thrombolytic treatment and percutaneous intervention are carried out so readily, it is important to remember that acute infarction is not the only cause of ST-segment elevation. The purpose of this review is to describe other conditions that mimic infarction and emphasize the electrocardiographic clues that can be used to differentiate them from true infarction.

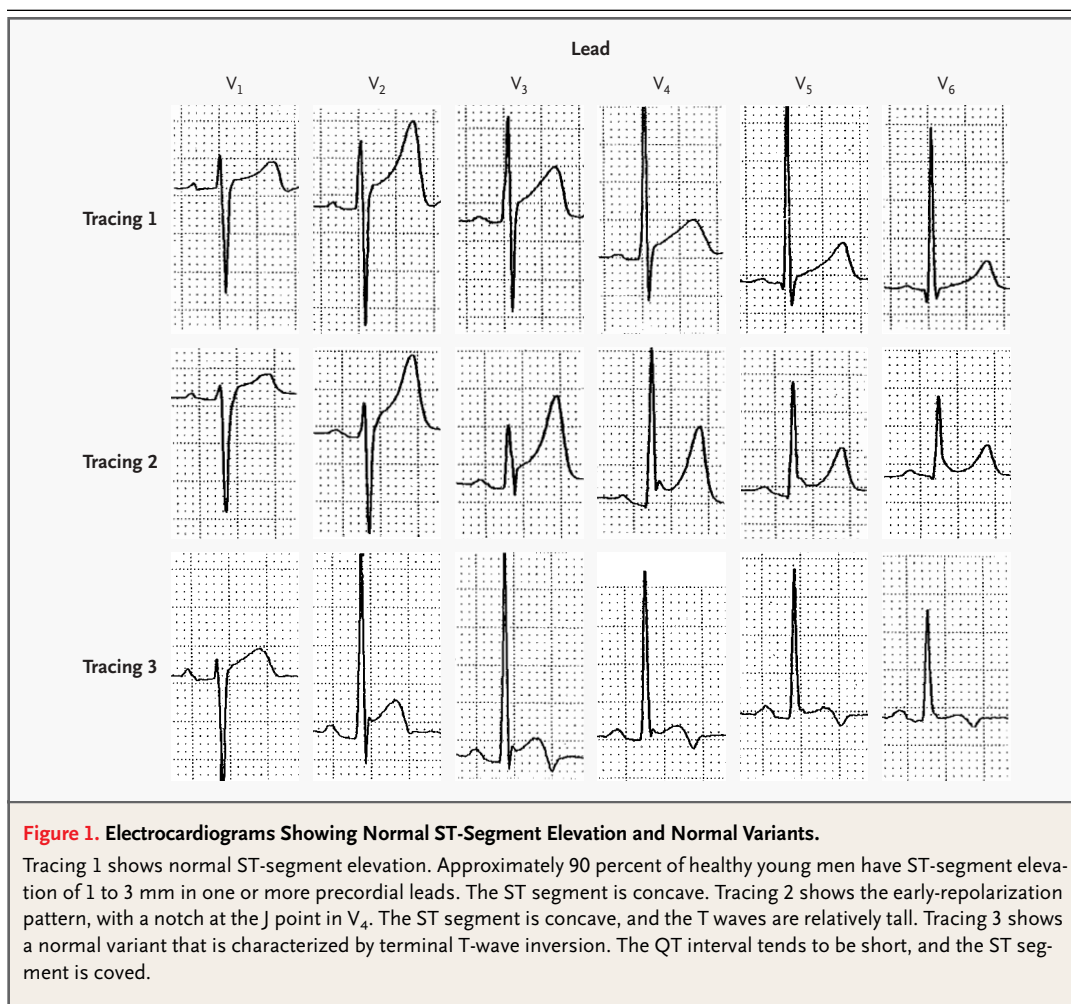
## NORMAL ST-SEGMENT ELEVATION AND NORMAL VARIANTS

The level of the ST segment should be measured in relation to the end of the PR segment, not the TP segment.<sup>5</sup> In this way, ST-segment deviation can still be detected accurately, even if the TP segment is not present because the P wave is superimposed on the T wave during sinus tachycardia or if the PR segment is depressed or there is a prominent atrial repolarization (Ta) wave.

Tracing 1 in Figure 1 is an example of normal ST-segment elevation. In a study of 6014 healthy men in the U.S. Air Force who were 16 to 58 years old, 91 percent had ST-segment elevation of 1 to 3 mm in one or more precordial leads.<sup>6</sup> The elevation was most common and marked in lead V<sub>2</sub>. In a recent study of normal electrocardiograms from 529 men, the prevalence of ST-segment elevation of at least 1 mm in one or more of leads V<sub>1</sub> through V<sub>4</sub> was 93 percent in the men who were 17 to 24 years old.<sup>7</sup> The prevalence declined gradually with increasing age, reaching 30 percent in men who were 76 years of age or older. In contrast, about 20 percent of normal electrocardiograms from women had ST-segment elevation of 1 mm or more, and this prevalence remained unchanged regardless of the women's ages.

Since the majority of men have ST elevation of 1 mm or more in precordial leads, it is a normal finding, not a normal variant, and is designated as a male pattern; ST elevation of less than 1 mm is designated as a female pattern.<sup>7</sup> In these patterns, the ST segment is concave. The deeper the S wave, the greater the ST-segment elevation — a relation that is often observed in patients with left ventricular hypertrophy (Fig. 2, tracing 1). Since the QRS vector loop is swung posteriorly in these patients, often resulting in a QS pattern in leads V<sub>1</sub> through V<sub>3</sub>, ST-segment elevation in these leads can be deceiving. In fact, left ventricular hypertrophy is one of the conditions that is most frequently mistaken for acute infarction. However, the elevated ST segment is concave in a patient with uncomplicated left ventricular hypertrophy as compared with convex in a patient with acute concomitant myocardial infarction.

In some healthy young people, especially in black men, the ST segment is elevated by 1 to 4 mm in the midprecordial leads as a normal variant. This pattern is commonly re-

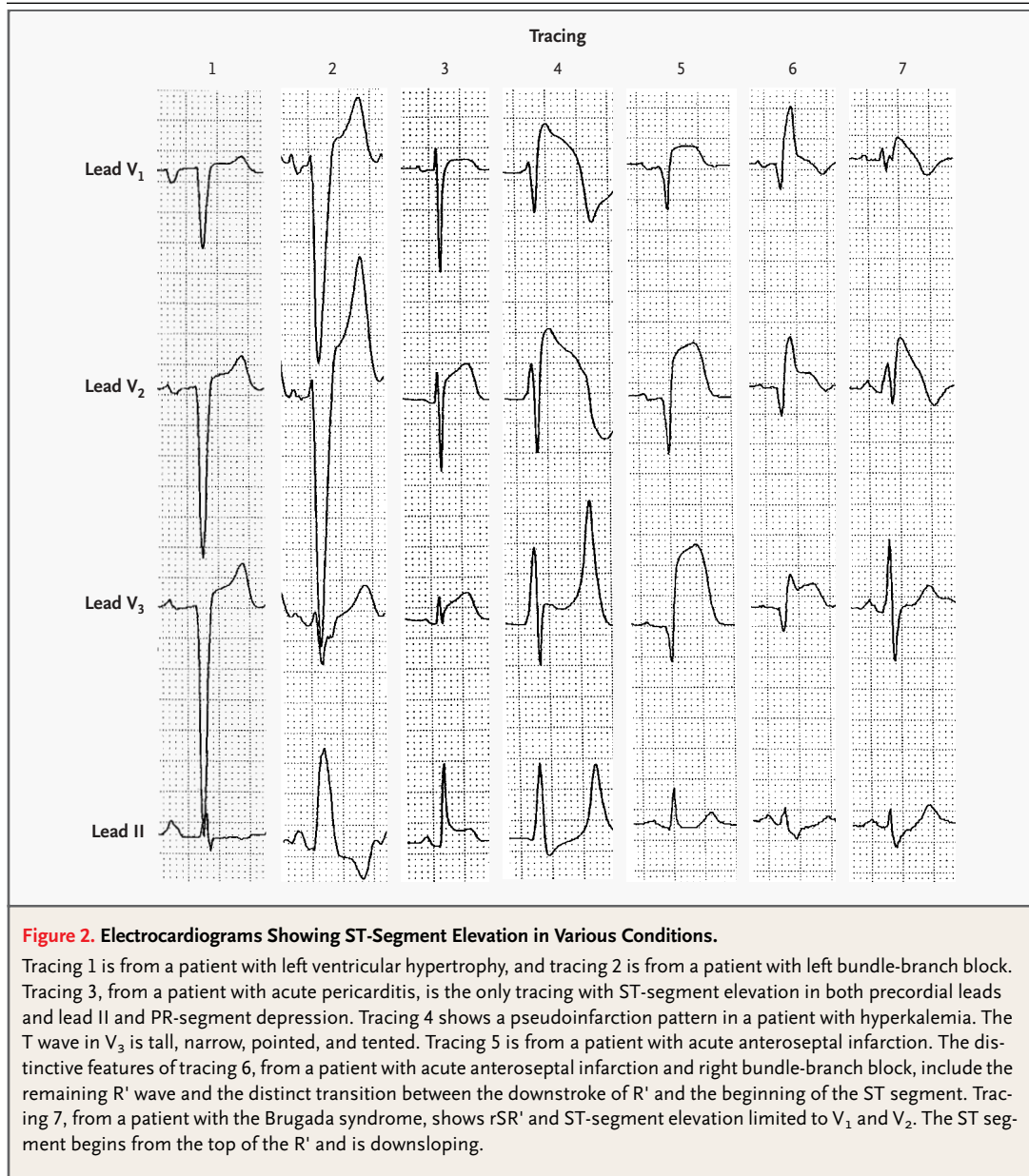


ferred to as early repolarization,<sup>8</sup> even though clinical studies have failed to demonstrate an earlier-than-normal onset of ventricular recovery.<sup>9</sup> Tracing 2 in Figure 1 is an example of the early-repolarization pattern. In most instances of early repolarization, the ST-segment elevation is most marked in V<sub>4</sub>, there is a notch at the J point (the junction between the QRS complex and the ST segment), and the ST segment is concave. The T waves are tall and are not inverted. Early repolarization of atrial tissue is also present, resulting in PR-segment depression. However, the PR-segment depression is not as marked as that in patients with acute pericarditis.<sup>10</sup> If this early-repolarization pattern involves limb leads, the ST segment is more elevated in lead II than in lead III and there is reciprocal ST segment depression in lead aVR but not in aVL, whereas in most patients with inferior infarctions, the ST segment is more el-

evated in lead III than in lead II and there is reciprocal ST-segment depression in lead aVL.

In some young black men, the ST segment is elevated in the midprecordial leads in combination with a T-wave inversion<sup>11,12</sup> as a normal variant (Fig. 1, tracing 3). This entity may be the combination of an early-repolarization pattern and a persistent juvenile T-wave pattern. Often, the findings are so suggestive of acute myocardial infarction that an echocardiogram is necessary to differentiate them, especially if one is not aware of this normal variant. In most cases of this normal variant, the QT interval is short, whereas it is not short in acute infarction or pericarditis. This normal variant differs from the early-repolarization pattern in that the T waves are inverted and the ST segment tends to be coved.

Thus, normally, in the precordial leads there can be no ST-segment elevation (or an elevation of less



than 1 mm, which is the female pattern) or there can be normal ST-segment elevation (1 mm or more, the male pattern), an early-repolarization pattern as a normal variant, or ST elevation of the normal variant. The electrocardiographic features are distinct (Fig. 1), even though some overlapping occurs. These ST-segment elevations meet the criterion for thrombolytic therapy according to the guidelines of the American College of Cardiology–American Heart Association<sup>13</sup>: “ST elevation greater than 0.1 mV in two or more contiguous leads.” Since

this criterion can be misleading, the Clinical Policies Subcommittee of the American College of Emergency Physicians added the qualifier “ST-segment elevations . . . that are not characteristic of early repolarization or pericarditis, nor of a repolarization abnormality from LVH [left ventricular hypertrophy] or BBB [bundle-branch block].”<sup>14</sup> Even this guideline does not address the normal ST-segment elevation in the right precordial leads that is present in many healthy persons.

---

 LEFT BUNDLE-BRANCH BLOCK
 

---

Making the diagnosis of acute infarction in the presence of left bundle-branch block can be problematic, since the ST segment is either elevated or depressed secondarily, simulating or masking an infarction pattern. These secondary ST-T changes are shifted to the opposite direction from the major component of the QRS complex (i.e., discordant). When these changes are concordant, they are specific for acute myocardial infarction.<sup>15,16</sup> However, in left bundle-branch block, the QRS complexes are mostly negative in leads V<sub>1</sub> to V<sub>3</sub>, and the ST-segment elevation from an anteroseptal infarction cannot be manifested as a concordant ST-segment shift. At times, replacement of the secondary concave ST segment with a convex ST segment may indicate an associated anteroseptal infarct. Another criterion that has been proposed for recognizing an associated anteroseptal infarct is ST-segment elevation of 5 mm or more.<sup>16</sup> However, tracing 2 in Figure 2 is from a patient who did not have an acute infarction, yet there is an ST-segment elevation of 8 mm in V<sub>2</sub>, demonstrating that the proposed criterion is not reliable. Madias et al. found that 6 percent of 128 patients with left bundle-branch block had ST-segment elevation of at least 5 mm in one or more of leads V<sub>1</sub> through V<sub>3</sub> in the absence of infarction.<sup>17</sup>

---

 ACUTE PERICARDITIS  
AND MYOCARDITIS
 

---

In patients with acute pericarditis, the ST segment is elevated diffusely in the precordial leads as well as in the limb leads, indicating involvement of more than one coronary vascular territory, which rarely happens in acute myocardial infarction (Fig. 2, tracing 3). In addition, the PR segment is depressed, and such depression is the atrial counterpart of ST-segment elevation. Diffuse pericarditis involves not only the subepicardial layer of the ventricular wall, which is responsible for the ST-segment elevation, but also the subepicardial layer of the atrial wall, which causes an atrial injury pattern. Depression of the PR segment, however, is not specific for acute pericarditis, since early repolarization or atrial infarction can also cause the depression. In patients with diffuse pericarditis, the ST-segment axis is often close to 45 degrees in the frontal plane,<sup>18</sup> which falls into the positive zone of both leads III and aVL, and the ST segment is elevated in both these leads and is also more elevated in lead II than in lead III.

In patients with acute inferior infarction, which is most often due to occlusion of the right coronary artery, the ST-segment axis is close to the axis of lead III,<sup>19-21</sup> which is opposite the axis of lead aVL; therefore, the ST-segment elevation in lead III is always associated with reciprocal ST-segment depression in leads aVL and I. In addition, the ST segment is more elevated in lead III than in lead II. In acute inferior infarction due to occlusion of the circumflex coronary artery, which accounts for about 20 percent of acute inferior infarctions, the axis of the ST segment is often close to that of aVF.<sup>21</sup> Accordingly, the ST segment is elevated to a similar degree in leads II and III, is equally depressed in leads aVR and aVL, and is not depressed in lead I. These rules are more reliable if the vessel is occluded proximally as opposed to distally. In high lateral infarction, the axis of the ST segment is close to that of aVL,<sup>19</sup> which is opposite the axis of lead III; the ST segment is elevated in aVL and is always reciprocally depressed in lead III. Thus, the ST-segment elevation in patients with infarction behaves reciprocally between leads III and aVL, whereas the ST-segment elevation in patients with acute pericarditis or early repolarization does not result in ST depression in aVL, though there is reciprocal depression in aVR. When pericarditis is localized, this rule does not apply. The ST-segment elevation in patients with pericarditis seldom exceeds 5 mm, whereas it may in patients with acute infarction. Also, in acute infarction, the PR segment is not depressed unless pericarditis supervenes or the atrial wall is also infarcted. Pericardial friction rub does not always indicate primary acute pericarditis, since it often accompanies a large, transmural acute myocardial infarction.

Acute myocarditis can cause diffuse ST-segment elevation, as does acute pericarditis. Furthermore, at times the prominent ST-segment elevation of acute myocarditis can simulate acute myocardial infarction.<sup>22</sup>

---

 HYPERKALEMIA
 

---

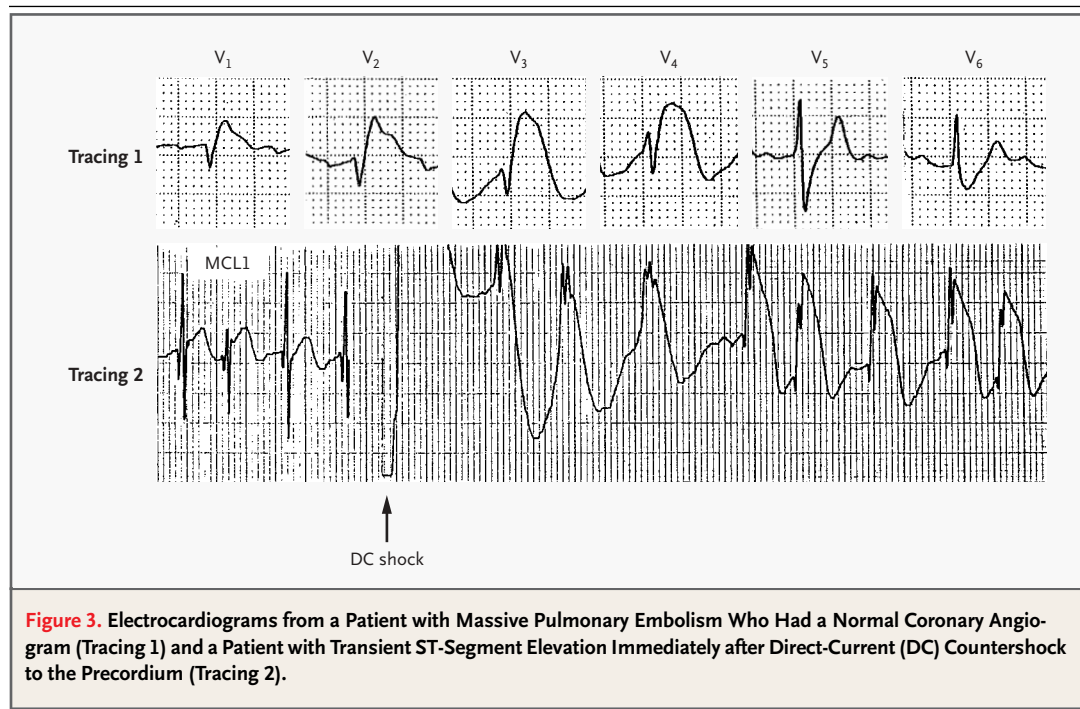
Hyperkalemia as a cause of ST-segment elevation is well recognized. In 1956, Levine et al. reported four cases of ST-segment elevation due to hyperkalemia resembling acute myocardial infarction or pericarditis, and they coined the term "dialyzable currents of injury."<sup>23</sup> Other electrocardiographic features of hyperkalemia that are often, but not always, present are widened QRS complexes; tall, pointed, and tent-

ed T waves; and low-amplitude or no P waves (Fig. 2, tracing 4). Even though the pseudoinfarction pattern of hyperkalemia is well known, the ST-segment elevation is so striking at times that one cannot help agonizing over the possibility of coexistent acute infarction. In patients with hyperkalemia, the elevated ST segment is often downsloping, a finding that is somewhat unusual in acute myocardial infarction, which is more likely to be characterized by an ST segment that has a plateau or a shoulder or is upsloping (Fig. 2, tracing 5). An echocardiogram can be extremely useful in this situation.

THE BRUGADA SYNDROME  
AND ARRHYTHMOGENIC RIGHT  
VENTRICULAR CARDIOMYOPATHY

In 1992, Brugada and Brugada described eight patients with a history of cardiac arrest and electrocardiographic findings of right bundle-branch block and ST-segment elevation in the right precordial leads in the absence of long QT intervals and any structural heart disease.<sup>24</sup> The disorder, known as the Brugada syndrome, accounts for 40 to 60 percent of all cases of idiopathic ventricular fibrillation.<sup>25</sup> The syndrome has been linked to mutations in the cardiac sodium-channel gene,<sup>25</sup> which re-

sult in a depression or a loss of the action-potential dome in the right ventricular epicardium but not in the endocardium, creating a transmural voltage gradient that is responsible for the ST-segment elevation in the right precordial leads and the genesis of ventricular fibrillation.<sup>26-28</sup> The Brugada syndrome is characterized by electrocardiographic abnormalities, and diagnostic criteria have been proposed.<sup>29</sup> In some patients, complete or incomplete right bundle-branch block is present. In others, the high-takeoff ST segment mimics the pattern of right bundle-branch block, but the wide S waves in leads I, aVL, and V<sub>6</sub> that are typically seen in right bundle-branch block are missing. The ST-segment elevation is primarily limited to leads V<sub>1</sub> and V<sub>2</sub> and can have a saddleback shape, but in typical cases the ST segment begins from the top of the R' wave, is downsloping, and ends with an inverted T wave (Fig. 2, tracing 7). This pattern is so distinctive that it should not be mistaken for acute infarction. In anteroseptal infarction complicated by right bundle-branch block, the downstroke of the R' wave and the beginning of the ST segment have a distinct transition, and the ST segment is horizontal or upsloping, not downsloping (Fig. 2, tracing 6). The ST-segment elevation in the Brugada syndrome may be present continuously or intermittently. So-



**Figure 3.** Electrocardiograms from a Patient with Massive Pulmonary Embolism Who Had a Normal Coronary Angiogram (Tracing 1) and a Patient with Transient ST-Segment Elevation Immediately after Direct-Current (DC) Countershock to the Precordium (Tracing 2).

dium-channel blockers such as ajmaline, flecainide, procainamide, and cocaine can unmask or induce this electrocardiographic pattern.<sup>30,31</sup>

An electrocardiographic pattern similar to that of the Brugada syndrome has been observed in some patients with arrhythmogenic right ventricular cardiomyopathy,<sup>32,33</sup> another condition associated with ventricular arrhythmias and sudden death. It may be difficult to distinguish this condition from the Brugada syndrome, since the replacement of the right ventricular myocardium with fibrofatty tissue, which is the hallmark of arrhythmogenic right ventricular cardiomyopathy, may be detected only at autopsy.<sup>29,32,33</sup> A similar electrocardiographic pattern has been observed in pulmonary embolism<sup>34</sup> and hyperkalemia.<sup>23</sup> Tarin et al. reported a case in which an electrocardiographic pattern like that of the Brugada syndrome was due to compression of the right ventricular outflow tract by a mediastinal tumor; the electrocardiographic findings became normal after removal of the tumor.<sup>35</sup>

#### PULMONARY EMBOLISM

The electrocardiographic features of pulmonary embolism include T-wave inversion in the right precordial leads; simultaneous T-wave inversion, ST-segment elevation, or both in the anteroseptal and inferior leads; an S<sub>1</sub>Q<sub>3</sub>T<sub>3</sub> pattern; complete or incomplete right bundle-branch block; and sinus tachycardia.<sup>34,36,37</sup> Tracing 1 in Figure 3 is from a patient with massive pulmonary embolism. The electrocardiographic findings were strongly suggestive of acute anterior infarction; a coronary angiogram, however, was normal. The electrocardiographic findings may have reflected right ventricular overload, dilation, or ischemia. Thus, a pseudoinfarction pattern can be a manifestation of pulmonary embolism.<sup>34,38</sup>

#### TRANSTHORACIC CARADIOVERSION

The ST segment can be elevated transiently after direct-current countershock to the precordium (Fig. 3, tracing 2). Van Gelder et al. reported that 23 of 146 patients with atrial fibrillation or flutter (16 percent) had ST-segment elevation of 5 mm or more after undergoing transthoracic cardioversion.<sup>39</sup> The ST segment normalized within a mean of 1.5 minutes (range, 10 seconds to 3 minutes). No clinical or enzyme evidence of myocardial injury was noted. Patients with ST-segment elevation had a lower con-

version rate than did those without elevation (48 percent vs. 76 percent) and were less likely to remain in sinus rhythm (35 percent vs. 59 percent). Kok et al. observed that transient ST-segment elevation occurred in 20 of 130 patients (15.4 percent) who were treated with transthoracic electrical countershock for ventricular tachyarrhythmias that were induced during electrophysiological study.<sup>40</sup> None of these patients had clinical evidence of an acute coronary event. The patients with ST-segment ele-

**Table 1. ST-Segment Elevation in Normal Circumstances and in Various Conditions.**

Condition	Features
Normal (so-called male pattern)	Seen in approximately 90 percent of healthy young men; therefore, normal Elevation of 1–3 mm Most marked in V <sub>2</sub> Concave
Early repolarization	Most marked in V <sub>4</sub> , with notching at J point Tall, upright T waves Reciprocal ST depression in aVR, not in aVL, when limb leads are involved
ST elevation of normal variant	Seen in V <sub>3</sub> through V <sub>5</sub> with inverted T waves Short QT, high QRS voltage
Left ventricular hypertrophy	Concave Other features of left ventricular hypertrophy
Left bundle-branch block	Concave ST-segment deviation discordant from the QRS
Acute pericarditis	Diffuse ST-segment elevation Reciprocal ST-segment depression in aVR, not in aVL Elevation seldom >5 mm PR-segment depression
Hyperkalemia	Other features of hyperkalemia present: Widened QRS and tall, peaked, tented T waves Low-amplitude or absent P waves ST segment usually downsloping
Brugada syndrome	rSR' in V <sub>1</sub> and V <sub>2</sub> ST-segment elevation in V <sub>1</sub> and V <sub>2</sub> , typically downsloping
Pulmonary embolism	Changes simulating myocardial infarction seen often in both inferior and anteroseptal leads
Cardioversion	Striking ST-segment elevation, often >10 mm, but lasting only a minute or two immediately after direct-current shock
Prinzmetal's angina	Same as ST-segment elevation in infarction, but transient
Acute myocardial infarction	ST segment with a plateau or shoulder or upsloping Reciprocal behavior between aVL and III

vation had a lower left ventricular ejection fraction than did those without elevation (27 percent vs. 35 percent). The mechanism of this ST-segment elevation is not clear.

---

#### PRINZMETAL'S ANGINA

---

When an epicardial artery is completely "pinched off" as a result of spasm, the ST segment becomes elevated in the leads facing the affected area, reflecting transmural ischemia. In this condition, called Prinzmetal's angina,<sup>41-43</sup> the spasm is usually brief and the ST segment returns to normal, with no resultant myocardial damage. The ST-segment elevations in Prinzmetal's angina and in acute infarction are indistinguishable, since they reflect the same pathophysiological process: transmural ischemia from occlusion of an epicardial artery by transient spasm in the first condition and by persistent thrombus in the second. If the spasm lasts long enough, infarction results.

---

#### CONCLUSIONS

---

Although many conditions affect the ST segment, it can respond in only two ways: it can become either elevated or depressed. There are several causes of ST-segment elevation besides acute myocardial infarction. Of patients with chest pain and ST-segment elevation, 171 of 202 patients (85 percent) in one study<sup>44</sup> and 63 of 123 (51 percent) in another study<sup>45</sup> had diagnoses other than infarction; the most com-

mon causes of ST-segment elevation were left ventricular hypertrophy, left bundle-branch block, early repolarization, and ventricular aneurysm. Some of these conditions can be misdiagnosed as acute infarction,<sup>46-48</sup> resulting in unwarranted thrombolytic therapy or emergency angiography. In two studies of consecutive patients treated with thrombolytic agents, 10 of 93 patients (11 percent) in one study<sup>49</sup> and 35 of 609 (5.7 percent) in the other study<sup>50</sup> did not have infarction. Left ventricular hypertrophy, early repolarization, conduction defect, and ventricular aneurysm (old infarction with persistent ST-segment elevation) were the most common causes of ST-segment elevation in these patients. Many times, the shape of the ST-segment elevation, the leads involved, other features of the electrocardiogram, the clinical setting in which the elevation occurs, and most important, awareness of the conditions that mimic infarction can help differentiate the conditions. In addition, echocardiography can sometimes be useful.

In patients with acute myocardial infarction and ST-segment elevation, the earlier reperfusion therapy is provided, the greater the benefit.<sup>51</sup> Since "time is myocardium,"<sup>52</sup> it is important to make the diagnosis as quickly as possible. It is equally important, however, not to confuse other causes of ST-segment elevation with acute myocardial infarction. The first step in the right direction is to be aware of such entities and to become familiar with the electrocardiographic features that distinguish them from infarction, as summarized in Table 1.

---

#### REFERENCES

- DeWood MA, Spores J, Notske R, et al. Prevalence of total coronary occlusion during the early hours of transmural myocardial infarction. *N Engl J Med* 1980;303:897-902.
- TIMI Study Group. The Thrombolysis in Myocardial Infarction (TIMI) trial: Phase I findings. *N Engl J Med* 1985;312:932-6.
- Gruppo Italiano per lo Studio della Streptochinasi nell'Infarto Miocardico (GISSI). Effectiveness of intravenous thrombolytic treatment in acute myocardial infarction. *Lancet* 1986;1:397-402.
- ISIS-2 Collaborative Group. Randomised trial of intravenous streptokinase, oral aspirin, both, or neither among 17,187 cases of suspected acute myocardial infarction: ISIS-2. *Lancet* 1988;2:349-60.
- Fletcher GF, Balady GJ, Amsterdam EA, et al. Exercise standards for testing and training: a statement for healthcare professionals from the American Heart Association. *Circulation* 2001;104:1694-740.
- Hiss RG, Lamb LE, Allen MF. Electrocardiographic findings in 67,375 asymptomatic subjects. *Am J Cardiol* 1960;6:200-31.
- Surawicz B, Parikh SR. Prevalence of male and female patterns of early ventricular repolarization in the normal ECG of males and females from childhood to old age. *J Am Coll Cardiol* 2002;40:1870-6.
- Kambara H, Phillips J. Long-term evaluation of early repolarization syndrome (normal variant RS-T segment elevation). *Am J Cardiol* 1976;38:157-61.
- Mirvis DM. Evaluation of normal variations in S-T segment patterns by body surface isopotential mapping: S-T segment elevation in absence of heart disease. *Am J Cardiol* 1982;50:122-8.
- Spodick DH. Differential characteristics of the electrocardiogram in early repolarization and acute pericarditis. *N Engl J Med* 1976;295:523-6.
- Goldman MJ. RS-T segment elevation in the mid- and left precordial leads as a normal variant. *Am Heart J* 1953;46:817-20.
- Chou T-C, Knilans TK. *Electrocardiography in clinical practice*. 4th ed. Philadelphia: Saunders, 1996:190.
- Ryan TJ, Anderson JL, Antman EM, et al. ACC/AHA guidelines for the management of patients with acute myocardial infarction: a report of the American College of Cardiology/American Heart Association Task Force on Practice Guidelines (Committee on Management of Acute Myocardial Infarction). *J Am Coll Cardiol* 1996;28:1328-428.
- Critical issues in the evaluation and management of adult patients presenting with suspected acute myocardial infarction or unstable angina. *Ann Emerg Med* 2000;35:521-5.
- Hands ME, Cook EF, Stone PH, et al. Electrocardiographic diagnosis of myocardial infarction in the presence of complete left bundle branch block. *Am Heart J* 1988;116:23-31.
- Sgarbossa EB, Pinski SL, Barbagelata A, et al. Electrocardiographic diagnosis of evol-

- ing acute myocardial infarction in the presence of left bundle-branch block. *N Engl J Med* 1996;334:481-7.
17. Madias JE, Sinha A, Agarwal H, Ashtiani R. ST-segment elevation in leads V1-V3 in patients with LBBB. *J Electrocardiol* 2001;34:87-8.
18. Hurst JW, Logue RB, Schant RC, Wenger NK, eds. *The heart, arteries, and veins*. 4th ed. New York: McGraw-Hill, 1978:1182.
19. *Idem*. *The heart, arteries, and veins*. 4th ed. New York: McGraw-Hill, 1978:1163.
20. Zimetbaum PJ, Krishnan S, Gold A, Carrozza JP II, Josephson ME. Usefulness of ST-segment elevation in lead III exceeding that of lead II for identifying the location of the totally occluded coronary artery in inferior wall myocardial infarction. *Am J Cardiol* 1998;81:918-9.
21. Chia BL, Yip JW, Tan HC, Lim YT. Usefulness of ST elevation II/III ratio and ST deviation in lead I for identifying the culprit artery in inferior wall acute myocardial infarction. *Am J Cardiol* 2000;86:341-3.
22. Spodick DH, Greene TO, Saperia G. Images in cardiovascular medicine: acute myocarditis masquerading as acute myocardial infarction. *Circulation* 1995;91:1886-7.
23. Levine HD, Wanzer SH, Merrill JP. Dialyzable currents of injury in potassium intoxication resembling acute myocardial infarction or pericarditis. *Circulation* 1956;13:29-36.
24. Brugada P, Brugada J. Right bundle branch block, persistent ST segment elevation and sudden cardiac death: a distinct clinical and electrocardiographic syndrome: a multicenter report. *J Am Coll Cardiol* 1992;20:1391-6.
25. Chen Q, Kirsch GE, Zhang D, et al. Genetic basis and molecular mechanism for idiopathic ventricular fibrillation. *Nature* 1998;392:293-6.
26. Yan GX, Antzelevitch C. Cellular basis for the Brugada syndrome and other mechanisms of arrhythmogenesis associated with ST-segment elevation. *Circulation* 1999;100:1660-6.
27. Alings M, Wilde A. "Brugada" syndrome: clinical data and suggested pathophysiological mechanism. *Circulation* 1999;99:666-73.
28. Gussak I, Antzelevitch C, Bjerregaard P, Towbin JA, Chaitman BR. The Brugada syndrome: clinical, electrophysiologic and genetic aspects. *J Am Coll Cardiol* 1999;33:5-15.
29. Wilde AA, Antzelevitch C, Borggrefe M, et al. Proposed diagnostic criteria for the Brugada syndrome: consensus report. *Circulation* 2002;106:2514-9.
30. Brugada R, Brugada J, Antzelevitch C, et al. Sodium channel blockers identify risk for sudden death in patients with ST-segment elevation and right bundle branch block but structurally normal hearts. *Circulation* 2000;101:510-5.
31. Littmann L, Monroe MH, Svenson RH. Brugada-type electrocardiographic pattern induced by cocaine. *Mayo Clin Proc* 2000;75:845-9.
32. Corrado D, Basso C, Buja G, Nava A, Rossi L, Thiene G. Right bundle branch block, right precordial ST-segment elevation, and sudden death in young people. *Circulation* 2001;103:710-7.
33. Tada H, Aihara N, Ohe T, et al. Arrhythmogenic right ventricular cardiomyopathy underlies syndrome of right bundle branch block, ST-segment elevation, and sudden death. *Am J Cardiol* 1998;81:519-22.
34. Sreeram N, Cheriex EC, Smeets JL, Gorgels AP, Wellens HJ. Value of the 12-lead electrocardiogram at hospital admission in the diagnosis of pulmonary embolism. *Am J Cardiol* 1994;73:298-303.
35. Tarin N, Farre J, Rubio JM, Tunon J, Castro-Dorticos J. Brugada-like electrocardiographic pattern in a patient with a mediastinal tumor. *Pacing Clin Electrophysiol* 1999;22:1264-6.
36. Ferrari E, Imbert A, Chevalier T, Mihoubi A, Morand B, Baudouy M. The ECG in pulmonary embolism: predictive value of negative T waves in precordial leads — 80 case reports. *Chest* 1997;111:537-43.
37. Rodger M, Makropoulos D, Turek M, et al. Diagnostic value of the electrocardiogram in suspected pulmonary embolism. *Am J Cardiol* 2000;86:807-9.
38. McLarin CW, Latting CA, Walter PF, Wenger NK. Pseudo anterior myocardial infarction as a manifestation of severe pulmonary embolism. *J Med Assoc Ga* 1981;70:649-53.
39. Van Gelder IC, Crijns HJ, Van der Laarse A, Van Gilst WH, Lie KI. Incidence and clinical significance of ST segment elevation after electrical cardioversion of atrial fibrillation and atrial flutter. *Am Heart J* 1991;121:51-6.
40. Kok LC, Mitchell MA, Haines DE, Mounsey JP, DiMarco JP. Transient ST elevation after transthoracic cardioversion in patients with hemodynamically unstable ventricular tachyarrhythmia. *Am J Cardiol* 2000;85:878-81.
41. Prinzmetal M, Kennamer R, Merliss R, Wada T, Bor N. A variant form of angina pectoris: preliminary report. *Am J Med* 1959;27:375-88.
42. Oliva PB, Potts DE, Pluss RG. Coronary arterial spasm in Prinzmetal angina: documentation by coronary arteriography. *N Engl J Med* 1973;288:745-51.
43. Maseri A, Severi S, Nes MD, et al. "Variant" angina: one aspect of a continuous spectrum of vasospastic myocardial ischemia: pathogenetic mechanisms, estimated incidence and clinical and coronary arteriographic findings in 138 patients. *Am J Cardiol* 1978;42:1019-35.
44. Brady W. ST-segment elevation in ED adult chest pain patients: etiology and diagnostic accuracy for AMI. *J Emerg Med* 1998;16:797-8. abstract.
45. Otto LA, Aufderheide TP. Evaluation of ST segment elevation criteria for the prehospital electrocardiographic diagnosis of acute myocardial infarction. *Ann Emerg Med* 1994;23:17-24.
46. Jayes RL Jr, Larsen GC, Beshansky JR, D'Agostino RB, Selker HP. Physician electrocardiogram reading in the emergency department — accuracy and effect on triage decisions: findings from a multicenter study. *J Gen Intern Med* 1992;7:387-92.
47. Brady WJ, Perron A, Ullman E. Errors in emergency physician interpretation of ST-segment elevation in emergency department chest pain patients. *Acad Emerg Med* 2000;7:1256-60.
48. Brady WJ, Perron AD, Chan T. Electrocardiographic ST-segment elevation: correct identification of acute myocardial infarction (AMI) and non-AMI syndromes by emergency physicians. *Acad Emerg Med* 2001;8:349-60.
49. Sharkey SW, Berger CR, Brunette DD, Henry TD. Impact of the electrocardiogram on the delivery of thrombolytic therapy for acute myocardial infarction. *Am J Cardiol* 1994;73:550-3.
50. Khoury NE, Borzak S, Gokli A, Havstad SL, Smith ST, Jones M. "Inadvertent" thrombolytic administration in patients without myocardial infarction: clinical features and outcome. *Ann Emerg Med* 1996;28:289-93.
51. Fu Y, Goodman S, Chang WC, Van De Werf F, Granger CB, Armstrong PW. Time to treatment influences the impact of ST-segment resolution on one-year prognosis: insights from the assessment of the safety and efficacy of a new thrombolytic (ASSENT-2) trial. *Circulation* 2001;104:2653-9.
52. Gibson CM. Time is myocardium and time is outcomes. *Circulation* 2001;104:2632-4.

Copyright © 2003 Massachusetts Medical Society.